

VOLUME 106 • AUGUST 2011 • ISSUE 2


—The Journal of—
*Prosthetic
Dentistry*



FEATURED ARTICLES

Comparative Radiopacity of
Ceramics

Gender differences in the
Form of Maxillary Central
Incisors



ISSN 0022-3913





SINGLE VISIT FABRICATION OF A PORCELAIN LAMINATE VENEER WITH CAD/CAM TECHNOLOGY: A CLINICAL REPORT

Dean Vafiadis, DDS,^a and Gary Goldstein, DDS^b

New York University College of Dentistry, New York, NY

Computer-assisted design and computer-assisted milling (CAD/CAM) technology has been shown to be an effective dental treatment adjunct. This article demonstrates its use in the fabrication of an in-office, one visit, porcelain laminate veneer. (J Prosthet Dent 2011;106:71-73)

Porcelain laminate veneers are fabricated with different techniques, all of which require an impression of the prepared tooth, an impression of the opposing arch, preparation of casts, and extensive laboratory time.¹⁻³ High survival rates for porcelain laminate veneer restorations have been reported.⁴⁻⁸ When a patient presents with trauma to natural teeth or fracture of previous restorations, color matching can be difficult. Despite the use of photography, drawings, and specific instructions that help the technician understand the adjacent tooth morphology and color,⁹⁻¹² communicating the hue, chroma, value, translucency, and texture to the laboratory is time consuming and may require multiple visits. The use of CAD/CAM technology to design a restoration in the dental office is more time efficient and may be more predictable.¹³⁻¹⁶ In addition, the fatigue resistance and tensile strength of CAD/CAM materials have been shown to be excellent.^{17,18} This clinical report demonstrates the fabrication of a CAD/CAM porcelain veneer in a single visit.

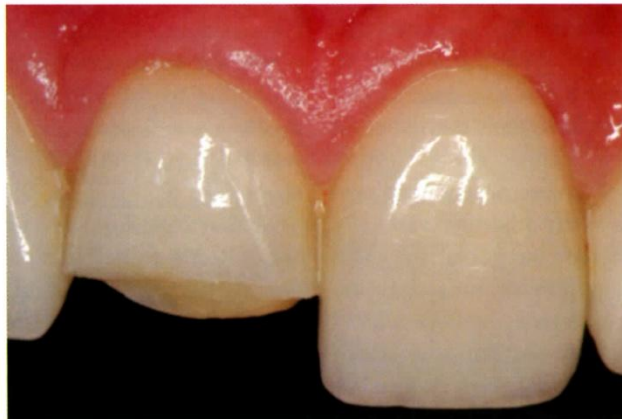CLINICAL REPORT

A 32-year-old, white female traumatically fractured the maxillary right central incisor 3 years after it and other anterior teeth had been restored

with porcelain laminate veneers to correct malalignment (Fig. 1). The patient was asymptomatic and no periapical radiolucency was evident on the radiographs.

Since the patient was a photographic model and was traveling abroad, a new porcelain laminate veneer was fabricated in a single treatment visit, with an intraoral scanner using computer-aided design (Cerec Blue-Cam AC; Sirona Dental Systems, Inc, Long Island City, NY). There are 2 methods for this type of CAD design that are specific to this system. The first is Biogeneric Mode, which uses a database of hundreds of maxillary central incisors that have been imported as a “library of shapes and forms.” The shape and form are cho-

sen by the clinician to best fit that patient’s tooth. The second design mode is Correlation Mode, which uses a cut and paste option of a scanned provisional restoration or diagnostic waxing of the desired tooth. This is the mode recommended for porcelain laminate veneer restorations because it helps capture the specific line angles, facial anatomy, and contour necessary for ideal esthetic anterior restorations and critical occlusal anatomy for posterior restorations.^{19,20} Correlation Mode requires an ideally contoured shape of the tooth to be scanned before the preparation of the tooth. For this patient, the ideal contours were developed intraorally with a flowable composite resin (Luxa-flow; DMG America, En-



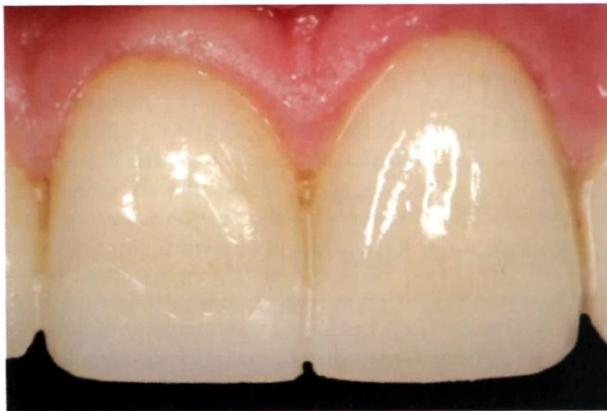1 Traumatic fracture of a preexisting porcelain laminate veneer on maxillary right central incisor.

Presented before the American Prosthodontic Society, February 2010, Chicago, Ill.

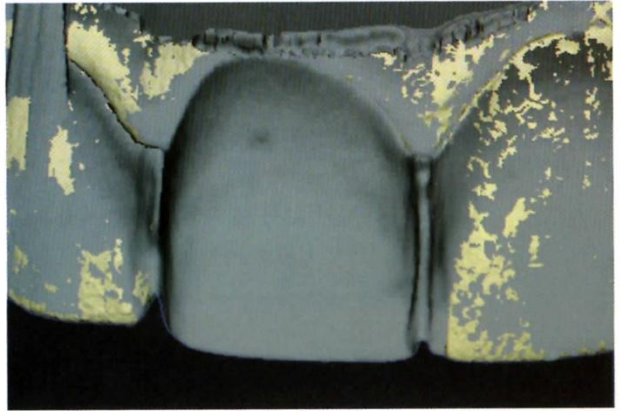
^aClinical Associate Professor, Department of Periodontics and Implant Dentistry.

^bProfessor, Department of Prosthodontics.

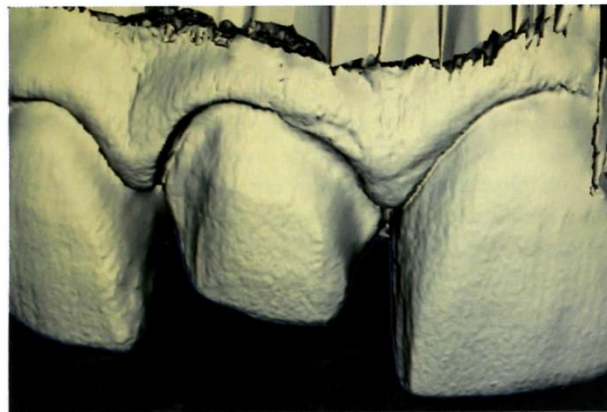



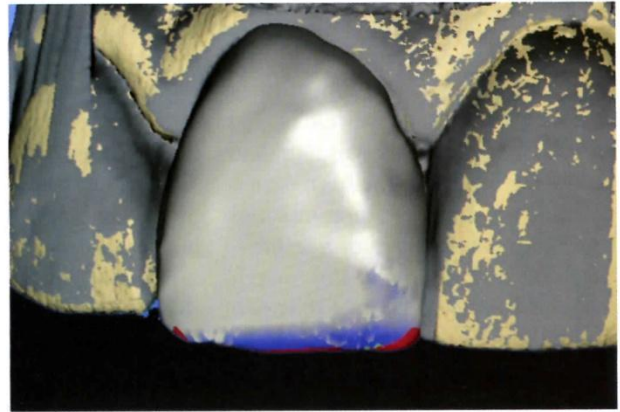
2 Ideal contoured composite resin to match shape and contour of adjoining teeth.



3 Ideal contoured composite resin foundation in correlation mode.



4 Tooth preparation.



5 Computer-assisted design of maxillary central.

glewood, NJ) to match the adjacent central incisor shape (Fig. 2).

The ideally contoured composite resin foundation was then sprayed with a white contrast powder (Vita Cerec Powder; VITA Zahnfabrik H. Rauter GmbH & Co. KG, Bad Säckingen, Germany), so that the intraoral blue camera scanner could capture the details of the restoration and other contours of the adjacent teeth.

Five different images of the ideal contoured composite resin foundation from different vantage points were captured in correlation mode in the *occlusion* window (Fig. 3). Five images of the interocclusal registration were captured in the *antagonist* window. The composite resin foundation was removed, the tooth was prepared to receive the porcelain laminate veneer, and 5 images of the preparation were captured in the *preparation* win-

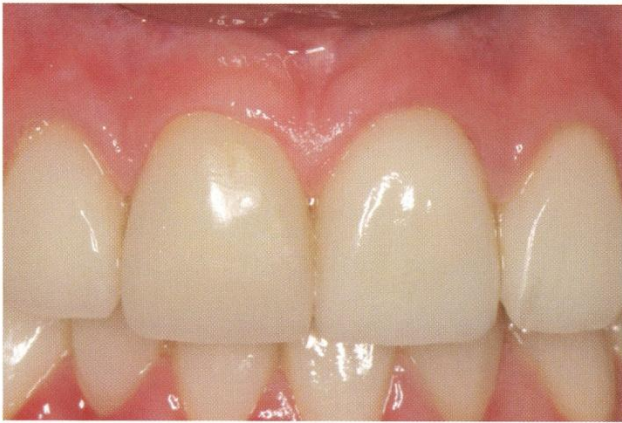dow (Fig. 4). In a process called “margination,” the design tool was used to follow and track the margins of the preparation identified by the clinician. In the CAD portion of the computer, the restoration was designed according to the original ideal composite resin foundation image that was captured through the correlation mode (Fig. 5).

A CAD/CAM block of the desired shade, translucency, and material was chosen. For this restoration, a block of porcelain (VITA Trifluor forte, shade 1M2; Vident, Brea, Calif) was used. This shade is equivalent to the VITA shade A1 (VITA 3D-Master Shade Guide; Vident). Milling of the laminate restoration was performed with a computer-assisted milling machine (MC XL; Sirona Dental Systems LLC, Charlotte, NC). Two different rotary cutting instruments were used for the

milling of the block - a 12S cylinder pointed instrument for bulk cutting and a 12S step instrument (Sirona Dental Systems LLC) for precision cuts. The milling process for this restoration was completed in 8.23 minutes.

The completed restoration was examined for proper fit, contour, and occlusion. Additional refining with a high speed handpiece (Star Dental, Lancaster, Pa) water irrigation and a fine diamond rotary cutting instrument (# 9809; Brasseler USA, Savannah, Ga) was necessary to obtain the proper shape and contour, so that the light reflection for the restoration matched the adjacent tooth.

Custom characterization (Viadent/Vita glaze and stain kit; Viadent) was accomplished and the restoration fired according to the manufacturer's specifications. The restoration was dried at 600°C for 2 minutes. Then



6 Final restoration after cementation.

the temperature was increased at the rate of 80°C/min for 4.26 minutes to 955°C and held for 1.4 minutes. Cooling time was 3 minutes. The total glaze phase was 11 minutes.

After the glazing cycle, the restoration was conditioned with a 9.6% hydrofluoric acid porcelain etch (Ultradent/Pulpdent Corporation, Watertown, Mass) and cemented with a shade B1, porcelain laminate veneer, light polymerizing cement (Variolink HighValue+2; Ivoclar Vivadent, Amherst, NY). The excess cement was trimmed, the occlusion verified, and the restoration polished with a 12-fluted carbide bur and porcelain polishing wheels (Brasseler USA) (Fig. 6).

DISCUSSION

A single visit protocol for the fabrication of a porcelain veneer allows the clinician to control color and contour and save time for both the patient and the clinician. Total patient chair time for this restoration was 1 hour and 45 minutes. While the savings in time and laboratory fees is compelling, this technique does require that a clinician has an apprecia-

tion of contouring and color matching - worthwhile skills that will assist the clinician in producing superior restorations. The characterization portion can be controlled with the various colors available; if the stain does not look correct, it can be easily rinsed off and reapplied. Single and multiple anterior porcelain laminate veneer restorations can be fabricated with this technique.

SUMMARY

A fractured porcelain laminate veneer was restored in a single visit with CAD/CAM technology.

REFERENCES

1. Calamia JR. Etched porcelain facial veneers: a new treatment modality based on scientific and clinical evidence. *NY J Dent* 1983;53:255-9.
2. Sorensen JA, Strutz JM, Avera SP, Materdomini D. Marginal fidelity and micro leakage of porcelain veneers made by two techniques. *J Prosthet Dent* 1992;67:16-22.
3. Garber D. Porcelain laminate veneers: Ten years later. Part 1. Tooth preparation. *J Esthet Dent* 1993;5:56-62.
4. Sheets CG, Taniguchi T. Advantages and limitations in the use of porcelain veneer restorations. *J Prosthet Dent* 1990;64:406-11.

5. Dumfhart H, Schäffer H. Porcelain laminate veneers: A retrospective evaluation 1 to 10 years of service: PartII--Clinical results. *Int J Prosthodont* 2000;13:9-18.
6. Layton D, Walton T. An up to 16-year prospective study of 304 porcelain veneers. *Int J Prosthodont* 2007;20:389-96.
7. Fradeani M. Six-year follow-up with Empress veneers. *Int J Periodontics Restorative Dent* 1998;18:216-25.
8. Kelly JR, Nishimura I, Campbell SD. Ceramics in dentistry: historical roots and current perspectives. *J Prosthet Dent* 1996;75:18-32.
9. Lee YK, Cha HS, Ahn JS. Layered color of all-ceramic core and veneer ceramics. *J Prosthet Dent* 2007;97:279-86.
10. Seghi RR, Johnston WM, O'Brien WJ. Spectrophotometer analysis of color differences between porcelain systems. *J Prosthet Dent* 1986;56:35-40.
11. Dozij A, Kleverlaan CJ, Meegdes M, van der Zel J, Feilzer AJ. The influence of porcelain layer thickness on the final shade of ceramic restorations. *J Prosthet Dent* 2003;90:563-70.
12. Douglas RD, Przybylska M. Predicting porcelain thickness required for dental shade matches. *J Prosthet Dent* 1999;82:143-9.
13. Willer J, Rossbach A, Weber HP. Computer-assisted milling of dental restorations using a new CAD/CAM data acquisition system. *J Prosthet Dent* 1998;80:346-353.
14. Isenberg BP, Essig ME, Leinfelder KF. Three-year clinical evaluation of CAD/CAM restorations. *J Esthet Dent* 1992;4:173-6.
15. Weidhahn K, Kerschbaum T, Fasbinder DJ. Clinical long-term results with 617 Cerec veneers: A nine-year report. *Int J Comput Dent* 2005;8:233-46.
16. Fasbinder DJ. Clinical performance of chairside CAD/CAM restorations. *J Am Dent Assoc* 2006;137:225-315.
17. Zahran M, El-Mowafy O, Tam L, Watson PA, Finer Y. Fracture strength and fatigue resistance of all-ceramic molar crowns manufactured with CAD/CAM technology. *J Prosthodont* 2008;17:370-7.
18. Chang JC, Estey AW, Chan JT. Tensile bond strength of five luting agents to two CAD/CAM restorative materials and enamel. *J Prosthet Dent* 2003;90:18-23.
19. Giordano R. Materials for chairside CAD/CAM produced restorations. *J Am Dent Assoc* 2006;137:145-215.
20. Potnicny DJ, Klim J. CAD/CAM in office technology: Innovations after 25 years for predictable, esthetic outcomes. *J Am Dent Assoc* 2010;141:55-95.

Corresponding author:

Dr Dean Vafiadis
693 Fifth Ave
14th Floor
New York, NY 10022
Fax: 212-319-4995
Email: drdean@nysi.org

Copyright © 2011 by the Editorial Council for
The Journal of Prosthetic Dentistry.