

*Dr. Lemongello- Please review and answer queries in red.
Thank you!!*

Correction Of An Adult Skeletal Class III Malocclusion Utilizing A Restorative Approach



*Gerard J.
Lemongello,
DMD*

Edward H. Angle described class III malocclusion as one in which the mandibular first molar is positioned mesially relative to the maxillary first molar.¹ A class III skeletal relationship can occur as a result of a normal maxilla with mandibular protrusion, maxillary retrusion with a normal mandible, or a combination of maxillary retrusion and mandibular protrusion. A class III dental relationship can exist when the maxillary/mandibular relationship is normal.

A pseudo class III malocclusion is caused by a forward shift of the mandible to avoid incisal interferences.² For many class III malocclusions, both surgical and orthodontic treatment are required. Depending on the amount of skeletal discrepancy, surgical correction may consist of mandibular retraction, maxillary protraction, or a combination of both procedures. For some minor class III malocclusions, or in the case of a pseudo class III malocclusion, surgical intervention may not be necessary.

Treatment objectives, whether utilizing surgery, orthodontic treatment, or restorative treatment, are the same: to correct the class III crossbite, create an ideal overjet/overbite relationship, achieve a dental class I occlusion, correct the midline, and restore the teeth to proper size and proportion. The objective is to provide the patient with an acceptable functional-occlusal relationship and an aesthetic dental/facial appearance.

Malocclusions are common. Patients with crowded and rotated teeth, spacing, or a crossbite who are unsatisfied with their appearance may not be interested in traditional orthodontic treatment or surgical correction. Their objections can be related to the length of time needed to complete treatment, or fear of extensive surgery with extended recuperation. When deciding upon treatment, the clinician must understand how the malocclusion affects the patient aesthetically, functionally, and biologically, and the long-term impact of treatment. Many patients may not require treatment. Others may need treatment to improve functions as well as improve the long-term prognosis of the teeth and stomatognathic

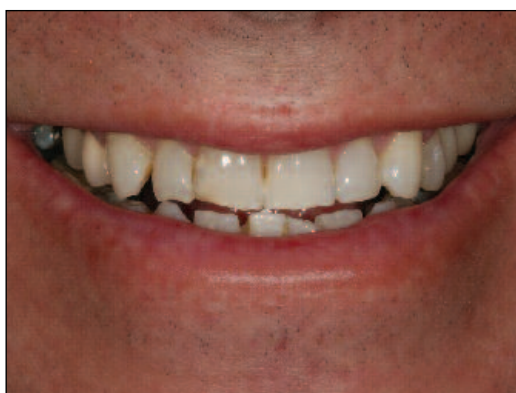

Figure 1. Smile View.

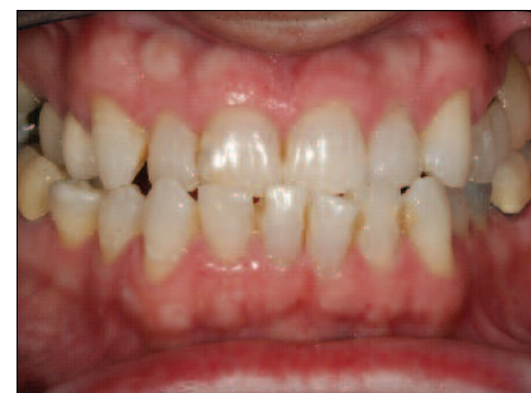

Figure 2. Retracted frontal view in occlusion.

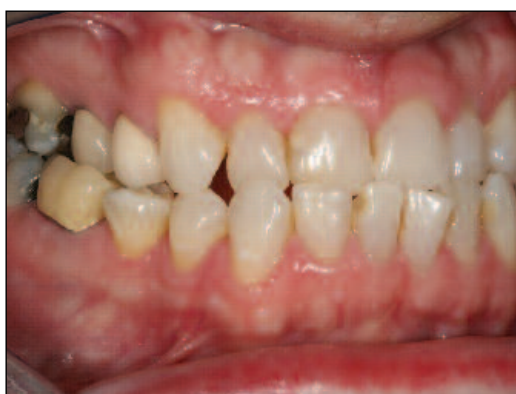

Figure 3. Retracted right lateral view in occlusion.

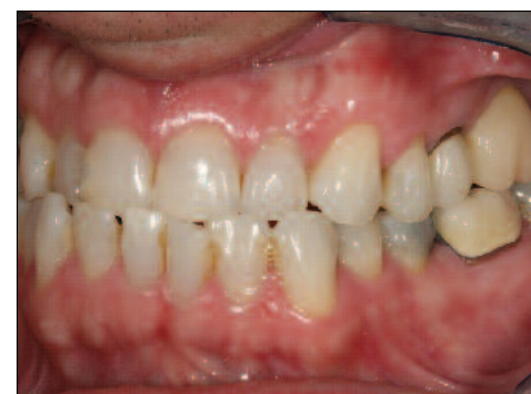

Figure 4. Retracted left lateral view in occlusion.

system. Still others may request treatment based solely on the desire to improve aesthetics. The practitioner must determine the benefits and consequences of each treatment option. It is important to speak with the patient, and determine when a noninvasive treatment plan may be optimal.

Once the patient understands and is fully informed of the treatment options, their benefits, and disadvantages, some individuals may desire treatment that does not involve orthodontics. In some cases, restorative techniques with veneers, crowns, or fixed prosthetics can provide exceptional strength, function, and aesthetics. The decision to proceed with restorative alignment of the teeth rather than orthodontic alignment is dependent on full disclosure and understanding of the treatment options, and the clinician's understanding of preparation design, aesthetics, and occlu-

sion.

CASE REPORT

History

A 47-year-old man presented with multiple dental problems ranging from recurrent caries, compromised periodontal health, occlusal trauma, and aesthetic concerns. He had begun to experience discomfort and had become concerned about the health of his teeth. In his 20s the patient had discussed orthodontic treatment and jaw surgery to correct his malocclusion, but elected not to receive treatment. Now in his 40s, the patient was unhappy with the appearance of his teeth and was interested in restoring his mouth to proper health without orthognathic surgery and orthodontics.

continued on page ##

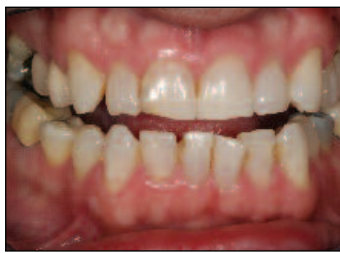

Figure 5. Pretreatment retracted view.

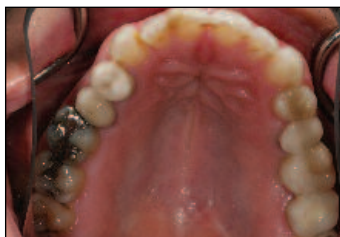

Figure 6. Maxillary occlusal view.

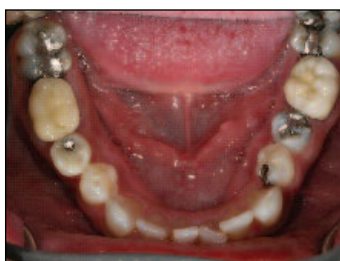

Figure 7. Mandibular occlusal view.

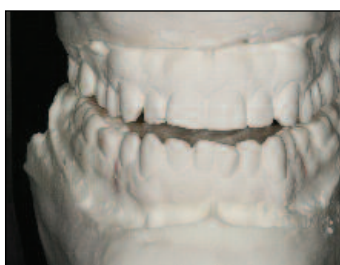

Figure 8. Pretreatment models mounted in centric relation at predetermined desired new vertical dimension.

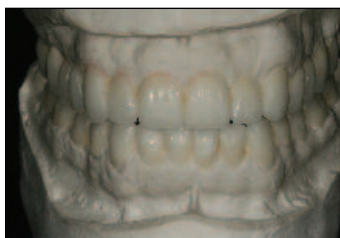


Figure 9. Pretreatment diagnostic wax-up.

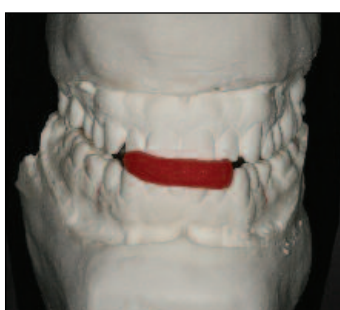

Figure 10. Pretreatment acrylic anterior centric relation jig preparation guide at desired new vertical dimension on mounted models.

Clinical Data

The patient was seen for a comprehensive examination including a full set of radiographs and digital photographs (Figures 1 to 7). The medical history was noncontributory. Evaluation of the temporomandibular joint revealed no history of previous problems and no current pathology. Jaw opening and range of motion were within normal limits. No joint sounds, signs, or symptoms of instability were evident. Head and neck, and muscles of mastication, were normal to palpation. Hard tissue examination revealed multiple restorations with recurrent caries. Tooth wear was evident throughout both arches. Occlusal examination revealed an anterior crossbite extending to a posterior crossbite on the left side. A class III cuspid and first molar relationship was present. Skeletal examination revealed a retrusive maxilla and protruded mandible (Figures 1 to 4). Examination of the face and profile revealed a shortened mid-face height and longer lower face length suggestive of a class III malocclusion.

The periodontal examination revealed generalized inflammation. Much of the inflammation was associated with the failing restorations. Aesthetically, the central incisors were not visible with the resting lip position, but the mandibular teeth were evident. A flat to reverse smile line was present, with the incisal plane being shorter than the occlusal plane. The length of the central incisors was short (measuring approximately 8 to 9 mm), these teeth were misshapen from wear, and not commensurate with the golden proportion.³ The color of the teeth did not complement the smile and were of low value.

Diagnosis

The diagnosis was a mutilated class III malocclusion with an asymmetrical anterior/posterior crossbite, aging restorations with recurrent caries that were in need of replacement, occlusal wear with possible loss of vertical dimension, and an unaesthetic smile.

Treatment Approaches

Prior to development of the definitive treatment plan the benefits and limitations of the 2 main treatment options were discussed with the patient: 1. orthodontic treatment followed by restorative dentistry, or 2. restorative dentistry alone. The benefits of orthodontic treatment with a restorative component would include less invasive restoration of the teeth. Nevertheless, it was obvious that once orthodontic treatment was complete, the patient would still require considerable restorative dentistry, specifically addressing recurrent caries in all 4 posterior sextants. The anterior dentition would require restoration due to wear and need to re-establish anterior/cuspid guidance. Lastly, with orthodontic treatment the shape and color of the existing dentition would remain the same, therefore not addressing one of the patient's main treatment goals—to improve the appearance of his smile. To achieve this goal the anterior teeth would require restoration, most likely porcelain veneers. Orthodontic treatment would also require an extended treatment time of at least 9 to 12 months, and at that point the result would be limited to preprosthetic aesthetics.

The benefits of the restorative dentistry option would address the failing restorations in all 4 posterior sextants. It would also allow restoration of the worn anterior dentition, which would also re-establish the anterior/cuspid guidance. The color of the dentition could be improved, addressing the goal of improving the color and shape of the teeth, and thereby the patient's smile. An extended treatment time would not be necessary with this option, with treatment completed in 3 to 6 weeks. The compromise with this treatment option would be the need for a more aggressive approach to tooth preparation, and all teeth would require restoration to correct the malocclusion. Financially, both options were equivalent, and there-

fore not an issue.

After consideration of both options, the patient elected to restore all teeth without orthodontic treatment.

Discussion

The treatment plan had 4 specific goals: 1. optimal oral health, 2. occlusal stability, 3. comfort when functioning, and 4. acceptable aesthetics. The relationship of the jaws and teeth should be analyzed to determine which segment/teeth is/are properly related to the cranial base and skeletal facial profile. The treatment goal is to maintain what is correctly aligned and change what is not. Analysis of the mounted casts is an important step. An important outcome is occlusal stability, with a focus on stable holding contacts for each tooth.⁴ Radiographic examination plays an important role as well, establishing biological health of the periodontium relative to pulpal, osseous, and structural concerns. Radiographic exam also provides analysis of skeletal relationships to aid in diagnosis and treatment.

When properly treated, crossbite relationships can be very stable, predictable, and maintainable. This is possible because the teeth are not being bodily moved through osseous tissue with retained memory of periodontal ligaments and other structures. Further, stability and maintainability are achieved through stable centric occlusion contacts. Crossbites can be divided into 2 categories: anterior crossbite and posterior crossbite, each with a different set of challenges and considerations. They may or may not occur together, and should be analyzed separately.⁴ Anterior and posterior crossbites are analyzed separately because they are evaluated by different criteria. Anterior crossbites are evaluated with regard to aesthetics, anterior centric contacts, and anterior guidance. Posterior crossbites are evaluated based on the teeth in relationship to the bone, tongue, and cheeks, and the occlusal relationship of maxillary teeth to

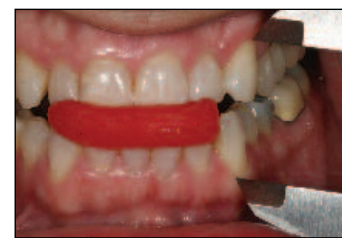

Figure 11. Anterior vertical dimension/centric relation jig. Digital caliper used to verify increase in vertical dimension within defined limits determined at diagnostic work-up phase.

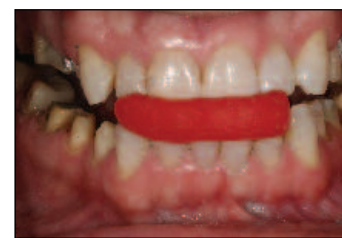

Figure 12. Preparation of the posterior teeth with the anterior teeth completely seated in the jig.

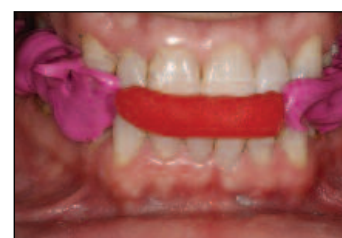

Figure 13. Bite relationship of the maxillary to mandibular posterior prepared teeth.

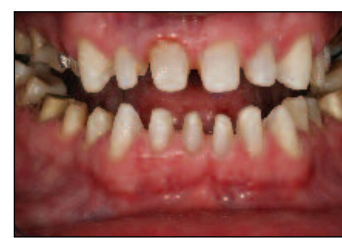

Figure 14. Maxillary and mandibular preparations.

mandibular teeth. A posterior crossbite may be a functional, stable relationship similar to a normal arch relationship, and may not require treatment. Evaluating anterior and posterior crossbites separately may reveal situations where correction of the crossbite (anterior or posterior) is not necessary to achieve the desired goal.

The potential problems associated with anterior crossbites are: aesthetics, absence of centric contact on anterior teeth or reversed anterior contacts, and lack of anterior guidance. Anterior crossbites do not provide anterior guidance in protrusive or lateral excursions.

continued on page XX

Xxxx...

continued from page

Class III malocclusions do not have traditional anterior/cuspid guidance, while class I and II occlusions do have this guidance. The class III patient does not use protrusive movements in a similar way to class I and class II patients who use these movements. Most class III patients limit their function to vertical movements and have a vertical functional pattern. They are vertical chewers with a vertical envelope of function because the class III malocclusion does not allow forward movement. Most crossbite patients do not use lateral functional movements similar to class I and class II occlusions. Regarding vertical movement, the goal is to maintain the posterior centric stop position from the previous class III in the new class I position relative to the vertical axis of the root. After treatment, the new class I occlusion should be designed and restored with minimal overjet and overbite, and minimal anterior guidance.

Additional consideration must be given to changes that occur in proprioception of the teeth and lips. With an anterior crossbite, when moving maxillary anterior teeth forward, there must be sufficient alveolar bone to support the new tooth position. The stresses exerted are reversed, so it may take time for the alveolar bone and periodontal ligament to realign to the new stresses. The teeth may be tender when functioning during the period of realignment, or just after.⁴

Another consideration when treating a crossbite, which is also a concern during rehabilitation, is the possibility of increasing the vertical dimension.⁵ Evaluation is required to determine if the vertical dimension should change. Changes in the vertical dimension may be required to correct a deep bite, level the occlusal plane, meet the prosthetic requirements for the selected restorative material(s), or change the anterior-posterior relationship of the anterior

or teeth when restoring anterior tooth position (as present in a class II or class III malocclusion).

Increasing the vertical dimension can help accomplish 2 goals when attempting to correct an anterior crossbite. First, increasing the vertical dimension causes the mandibular anterior teeth to move down and away from the lingual of the maxillary anterior teeth along the arc of opening and closing path while the condyles are in centric relation. This will allow the mandibular incisors to be more in line with the maxillary anterior teeth, helping to correct the anterior crossbite. The second is improved aesthetics. Many patients with an anterior crossbite have short clinical crowns. By increasing the vertical dimension, room is created to lengthen the teeth and improve aesthetics. When establishing the occlusal plane it is better to keep the Curve of Wilson and Curve of Spee relatively flat and on an even plane (one that is more shallow).⁶

Treatment Plan

The treatment plan would be a full-mouth restoration of all remaining teeth with crowns, bridges, onlays, onlay veneers, and porcelain veneers to correct the class III crossbite, restore carious and worn teeth, restore anterior/cuspid guidance, and improve aesthetics. Initial treatment would consist of a diagnostic workup, including models mounted by facebow transfer to a semi-adjustable articulator in centric relation. Occlusal analysis of the mounted models would be performed to identify the skeletal and dental relationship. This would allow determination of how much (if any) the vertical dimension of occlusion would need to be opened to restore the maxillary and mandibular arch form, and correct the crossbite.

The Challenges

The challenges discussed with the patient prior to treatment included: change in speech, change in sensation of the upper lip as a result of the new position of

the teeth, the effect of the new jaw position on the TMJ and muscles of mastication, increased vertical dimension, and sensation of centric stops on the anterior teeth (the patient had never experienced these contacts). When treating any full mouth restorative case where vertical dimension is to be changed, caution should be made not to increase vertical dimension more than is necessary. In this case the goal was to increase the posterior vertical dimension no more than one mm. Opening the vertical dimension by this minimal amount should not have an adverse effect on the TMJ. If the joint is comfortable at the existing vertical dimension, it is unlikely that the joint will experience any discomfort at an altered vertical dimension.⁷⁻⁹ Also, it has been shown that altering the vertical dimension in this manner does not produce muscle pain.¹⁰⁻¹² Alteration of the vertical dimension is generally measured at the anterior teeth. It has been shown that a 3 mm change in the vertical dimension in the anterior region results in a one-mm change in the length of the masseter muscles. This is well tolerated.¹³ It is advisable to discuss with the patient the anticipated changes in speech, altered tooth sensation, and bite sensation. The period of adjustment may be a few months with restorative dentistry, and may be more easily tolerated than the adjustment following orthognathic surgery and orthodontic treatment.

Pretreatment Phase

A complete pretreatment analysis is essential when restoring an anterior crossbite. A wax-up of all anterior teeth should be accomplished that represents the final contours and tooth position.

Instructions were forwarded to the laboratory with all diagnostic materials including photographs and mounted models in centric relation. The instructions included a description of soft tissue changes, desired length of the central inci-

sors, maxillary and mandibular arch form changes, anterior tooth proportions, molar relationships, overjet and overbite dimensions, anterior/cuspid guidance requirements, and amount of increase in the vertical dimension (Figure 8). A diagnostic wax-up would be required to visualize the outcome (Figure 9).

In addition to the diagnostic wax-up, fabrication of an acrylic anterior centric relation jig capturing the new vertical dimension of the maxillary and mandibular teeth was requested. This jig would become the preparation guide, providing a vertical stop at the new vertical dimension in centric relation (Figure 10). The diagnostic wax-up would serve as the restorative blueprint for progression of the case through the preparation, provisional, and restorative phases. A putty matrix of the diagnostic wax-up would be made of both arches, to be used in the fabrication of the provisional restorations. With the diagnostic wax-up, anterior vertical dimension/centric relation jig, and putty matrices fabricated, the patient could be appointed to prepare and provisionalize both the maxillary and mandibular arches simultaneously. The patient's tolerance to the new vertical dimension and occlusal scheme would be evaluated, which would then be followed by the definitive restorative phase.

Treatment

Preparation

Before administering anesthesia, the anterior vertical dimension/centric relation jig was tried in place to evaluate the planned new vertical dimension. With the jig secure, a digital caliper was used to verify that the increase in vertical dimension was within the defined limits initially decided upon at the diagnostic work-up phase.^{6,14} (Figure 11).

This measurement was compared and verified against the existing vertical dimension to verify the increase in vertical dimension within defined limits that was determined at the

diagnostic work-up phase.

Once the new vertical dimension was confirmed, anesthetic was administered. Preparation of all maxillary and mandibular posterior teeth was accomplished utilizing the anterior vertical dimension/centric relation jig on the maxillary and mandibular anterior teeth as a guide (Figure 12).

With preparation of the posterior teeth complete, and the anterior teeth completely seated in the jig, a bite relationship of the maxillary to mandibular posterior prepared teeth was taken in a stiff polyvinyl bite registration material (Figure 13). The bilateral bite registration material would become the posterior guide for restoring the case. The anterior jig was removed and all remaining maxillary and mandibular anterior teeth were prepared (Figure 14).

Once this was completed, all posterior teeth were seated into the bite registration. An anterior bite registration was then created, indexing the prepared maxillary and mandibular teeth (Figure 15). With both the anterior and posterior bite registrations in place, a measurement was made with the digital caliper verifying the vertical dimension measurement.

A polyether impression material was then used to capture both the maxillary and mandibular prepared teeth. A facebow transfer was taken of the maxillary arch to allow mounting of the maxillary master cast to the articulator. Digital photographs of the prepared teeth and stump shade were taken. The provisional restoration was then prepared.

Provisionalization

The provisional restoration was fabricated utilizing a putty matrix made from the diagnostic wax-up. The provisional was removed from the matrix and separated into 2 posterior segments and 1 anterior segment for both the maxillary and mandibular arches, and trimmed appropriately. The maxillary and mandibular anterior segments were returned to the mouth. With

both segments in place, an initial equilibration was performed on the provisional. Adjustment in this way acts as an anterior jig, allowing the condyle to position in centric relation at this vertical dimension. Measurement with the digital caliper was made, verifying that the vertical dimension had remained the same. With the vertical dimension and centric relation verified, the maxillary and mandibular posterior provisional segments were tried in. The posterior provisional segments were equilibrated until equal centric holding contacts were recorded on all posterior and anterior teeth. Anterior and cuspid guidance were then established, which completed the occlusal adjustment.

All segments of the provisional restoration were removed and prepared for cementation. The maxillary and mandibular anterior veneer segments would be tacked by spot etching with 35% phosphoric acid, bonded with unfilled resin and flowable composite, cleaned to satisfaction, and light cured into place. The posterior provisionals were cemented with provisional cement. With the occlusal adjustments complete, aesthetic re-contouring of the provisional was performed. The provisional was then polished and glazed to satisfaction (Figures 16 and 17).

The patient was dismissed and reappointed the next day for evaluation of the provisional restoration. The final impressions, face-bow transfer, and bite registration were forwarded to the laboratory with instructions to create and mount the master models. The laboratory was advised that models and photographs of the provisional would be forwarded in the future, after patient acceptance of the new vertical dimension and occlusal scheme could be verified.

The patient presented for evaluation of the provisional in regard to aesthetics, phonetics, and function. The patient was very satisfied with the aesthetics. Regarding speech, the "S" position was verified and the

patient was able to accommodate to the new incisal edge position with minimal phonetic problems.^{13,15,16} The patient was aware of the maxillary teeth against the inside of the upper lip, and accommodated well. The patient expressed that time was needed to adjust to the new vertical dimension and occlusal scheme, as this felt foreign. With the aesthetics and phonetics acceptable, the occlusion was re-evaluated utilizing the Tekscan. Adjustments were made with the Tekscan to provide equal intensity centric contacts.^{17,18} The patient was then released and scheduled for another evaluation in one week.

The patient presented for the one-week follow-up appointment. The vertical dimension was comfortable but the patient still expressed difficulty adjusting to the new occlusal scheme. The evaluation revealed that cuspid guidance was not comfortable. Adjustments were made, converting cuspid guidance to group function with lateral excursive movements distributed across the first molar, bicuspid, and cuspid. The Tekscan was utilized to assist with the occlusal adjustments. Once these adjustments were completed the patient was comfortable. The patient was scheduled 2 weeks later to verify comfort with the new occlusion. This was accomplished, and models and photographs of the provisional were forwarded to the laboratory with instructions for fabrication of the final restorations. Instruction included fabrication of porcelain to gold crowns for all molars, zirconia crowns for all bicuspid, and feldspathic porcelain veneers for all cuspids and incisors.

Final Restoration Evaluation and Cementation

All restorations were returned from the ceramist and inspected for accuracy prior to final delivery. All restorations were acceptable in regard to fit and contact on the master model. The patient presented for the cementation appointment. Anesthesia was adminis-

tered and the provisional restorations were removed. The veneers were initially tried on teeth Nos. 8 and 9 to check fit and accuracy. The remaining veneers, crowns, and fixed partial denture were also tried in to inspect the fit of all restorations. The patient was asked to bite together gently to verify occlusion and vertical dimension. Although occlusal adjustments were required, the occlusal position and vertical dimension were acceptable. The veneers were tried in with a veneer try-in paste and inspected for shade match to the other restorations. The veneers and crowns were then removed from the mouth. All posterior restorations were placed first on a quadrant-by-quadrant basis.

After appropriate setting time all excess cement was removed. W2 rubber dam clamps were placed on the maxillary first bicuspid and a rubber dam was placed utilizing the split rubber dam technique.^{19,20} The maxillary veneers were bonded utilizing acceptable wet bonding techniques, maintaining a moist surface.²¹⁻²³ The "rapid cementation" technique as described by Rosenthal¹⁹ was used to bond all veneers. The W2 rubber dam clamps were placed on the mandibular first bicuspid and the rubber dam was placed on the mandibular teeth. The mandibular veneers were bonded utilizing the same technique and sequence as described for the maxillary veneers.^{19,20-23} Once all restorations were secure the occlusion was adjusted to achieve proper centric contacts and establish proper anterior and lateral guidance.²⁴ Lateral excursions were established as group function with excursive contact on the first molar to cuspids.

The patient was given postoperative instructions, and an appointment was made for evaluation in 24 hours. The next day the teeth were inspected for aesthetics, phonetics, and function. With the aesthetics and phonetics acceptable, the occlusion was re-evaluated utilizing the Tekscan.

Adjustments were made to provide equal time-intensity centric contacts.^{17,18} The patient was scheduled for evaluation in one week, at which impressions would be made to fabricate a night guard. The final result was excellent and well accepted by the patient (Figures 18-20).

SUMMARY AND CONCLUSION

When determining if treatment for malocclusion is indicated, the clinician must understand how the malocclusion affects the patient aesthetically, functionally, and biologically, as well as any impact of treatment. It is important to consult the patient and advise when a less invasive orthodontic treatment plan may be optimal. Once the patient is fully informed of the treatment options and desires treatment without orthodontics, a restorative/prosthetic approach using veneers, crowns, or fixed prosthetics can provide exceptional strength, function, and aesthetics. As in all cases, thorough evaluation and planning are essential.

The decision to proceed with restorative alignment of the teeth rather than orthodontic alignment is dependent on full disclosure to the patient and the clinician's understanding of preparation design, aesthetics, and occlusion. As demonstrated in this Class III case, with proper examination, diagnosis, treatment planning, and communication, excellent aesthetic, phonetic, and functional results can be achieved and maintained. As with all full mouth restorative cases, periodic occlusal evaluation will be necessary at normal hygiene intervals. ♦

References

1. Angle EH. *Treatment of Malocclusion of the Teeth and Fractures of the Maxillae, Angle's System*. 6th ed. Philadelphia, PA: SS White Dental Manufacturing; 1900:5-15.
2. Proffit WR. *Contemporary Orthodontics*. St Louis, MO: Mosby; 1986:47-49.
3. Rufenacht C. *Fundamentals of Esthetics*. Chicago, IL: Quintessence; 1990.
4. Dawson PE. *Evaluation, Diagnosis, and Treatment of Occlusal Problems*. 2nd ed. St Louis, MO: Mosby; 1989:555-567.
5. Kois JC, Phillips KM. Occlusal vertical dimension: alteration concerns.

6. Spear FM. Approaches to vertical dimension. *Inside Dentistry*. 2007;3(7):34-44. [AUTHOR: Please verify.]
7. Rivera-Morales WC, Mohl ND. Relationship of occlusal vertical dimension to the health of the masticatory system. *J Prosthet Dent*. 1991;65:547-553.
8. Kovaleski WC, DeBoever J. Influence of occlusal splints on jaw position and musculature in patients with temporomandibular joint dysfunction. *J Prosthet Dent*. 1975;33:321-327.
9. Manns A, Miralles R, Santander H, et al. Influence of the vertical dimension in the treatment of myofascial pain-dysfunction syndrome. *J Prosthet Dent*. 1983;50:700-709.
10. Helling G. Functional adaptation to changes in vertical dimension. *J Prosthet Dent*. 1984;52:867-870.
11. Gamon JA, Wright SM. Perception of vertical dimension. *J Oral Rehabil*. 1982;9:307-316.
12. Tryde G, Stoltze K, Fujii H, et al. Short-term changes in the perception of comfortable mandibular occlusal positions. *J Oral Rehabil*. 1977;4:17-21.
13. Spear FM. Occlusion in clinical practice. Seminar presented at: Seattle Institute for Advanced Dental Education; October 2001; Orlando, FL.
14. Lee RL. Esthetics and its relationship to function. In: Rufenacht CR, ed. *Fundamentals of Esthetics*. Chicago, IL: Quintessence; 1990:137-209.
15. Hammond RJ, Beder OE. Increased vertical dimension and speech articulation errors. *J Prosthet Dent*. 1984;52:401-406.
16. Howell PG. Incisal relationships during speech. *J Prosthet Dent*. 1986;56:93-99.
17. Kerstein RB, Grundset K. Obtaining bilateral simultaneous occlusal contacts with computer analyzed and guided occlusal adjustments. *Quintessence Int*. 2001;32:7-18.
18. Carey JP, Craig M, Kerstein RB, et al. Determining a relationship between applied occlusal load and articulating paper mark area. *The Open Dentistry Journal*. 2007;1:1-7.
19. Rosenthal L. Syllabus for the Aesthetic Advantage Continuum. Paper presented at: Postgraduate seminar at the Atlantic Coast Research Clinic. March 1998; West Palm Beach, FL. [AUTHOR: Please verify.]
20. Rosenthal L. The state of the art in advanced porcelain veneering: part 2. *Esthetic Dentistry Update*. 1991;2(6):96-101. [AUTHOR: Please verify.]
21. Kanca J III. Improving bond strength through acid etching of dentin and bonding to wet dentin surfaces. *J Am Dent Assoc*. 1992;123:35-43.
22. Kanca J III. Resin bonding to wet substrate. 1. Bonding to dentin. *Quintessence Int*. 1992;23:39-41.
23. Gwinnett AJ. Moist versus dry dentin: its effect on shear bond strength. *Am J Dent*. 1992;5:127-129.
24. Dawson PE. *Evaluation, Diagnosis, and Treatment of Occlusal Problems*. 2nd ed. St Louis, MO: Mosby; 1989:555-567; 592-607.

Dr. Lemongello graduated from the University of Florida, College of Dentistry and has been in private practice since 1987. His focus is on cosmetic and comprehensive restorative rehabilitative dentistry. He is a Clinical Instructor with the Rosenthal Institute's Aesthetic Advantage Continuum at New York University. He can be reached at (561) 627-9000 or drlmngello@aol.com.

Xxxx...

continued from page

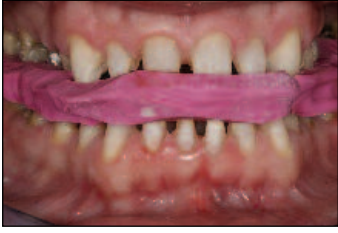

Figure 15. Posterior teeth seated into bite registration. An anterior bite registration is then created, indexing the prepared maxillary and mandibular teeth.

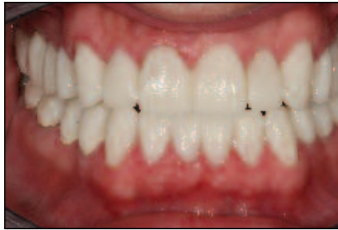

Figure 16. Provisional, frontal retracted view in occlusion.

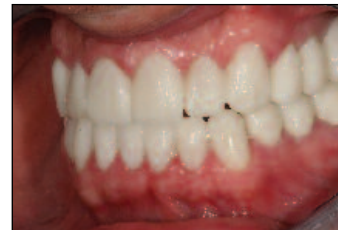

Figure 17. Provisional, left lateral view in occlusion.

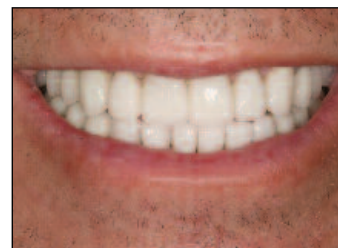

Figure 18. Final restoration, smile view.

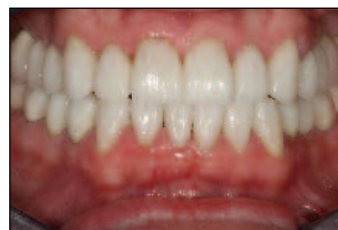

Figure 19. Final restoration, retracted view.

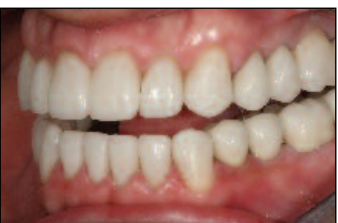

Figure 20. Final restoration, retracted left lateral view.

Continuing Education

Test No. 98.#



To submit Continuing Education answers, use the answer sheet on page xx. On the answer sheet, identify the article (this one is Test 98.#), place an X in the box corresponding to the answer you believe is correct, detach the answer sheet from the magazine, and mail to Dentistry Today Department of Continuing Education.

The following 8 questions were derived from the article *Correction Of An Adult Skeletal Class III Malocclusion Utilizing A Restorative Approach* by Gerard J. Lemongello, DMD on pages xx through xx.

Learning Objectives

After reading this article, the individual will learn:

- The importance of understanding how malocclusion affects the patient aesthetically, functionally, and biologically, and the long-term impact of treatment.
- A treatment protocol that provided a patient with an acceptable functional-occlusal relationship and an aesthetic dental/facial appearance.

- A class III skeletal relationship can occur as a result of:**
 - a normal maxilla with mandibular protrusion.
 - maxillary retrusion with a normal mandible.
 - a combination of maxillary retrusion and mandibular protrusion.
 - all of the above.
- The decision to proceed with restorative alignment of the teeth rather than orthodontic alignment is dependent on:**
 - full disclosure and understanding of the treatment options.
 - the clinician's understanding of preparation design.
 - aesthetics, and occlusion.
 - all of the above.
- What compromise exists when utilizing a restorative option to correct a malocclusion vs. orthodontic treatment?**
 - the need for a more aggressive approach to tooth preparation.
 - there is no compromise to restorative treatment.
 - restorative treatment takes longer to complete.
 - all of the above.
- The treatment plan in this article had 4 specific goals: Which goal is NOT correct?**
 - optimal oral health.
 - occlusal instability.
 - comfort when functioning.
 - acceptable aesthetics.
- The potential problems associated with anterior crossbites are:**
 - aesthetics.
 - absence of centric contact on anterior teeth, or reversed anterior contacts.
 - lack of anterior guidance.
 - all of the above.
- When converting a class III malocclusion to a new class I the occlusion should be designed and restored with:**
 - minimal overjet and overbite.
 - minimal anterior guidance.
 - 5 mm of overjet and 90% overbite.
 - a and b.
- In the case presented, the challenges discussed with the patient prior to treatment included:**
 - change in speech.
 - change in sensation of the upper lip as a result of the new position of the teeth.
 - the effect of the new jaw position on the muscles of mastication, increased vertical dimension, and sensation of centric stops on the anterior teeth.
 - all of the above.
- Caution should be made not to increase vertical dimension more than is necessary. A 3 mm opening of the vertical in the anterior segment should:**
 - not have an adverse effect on the TMJ.
 - not produce muscle tension.
 - result in a 1 mm change in the length of the masseter muscles, which is well tolerated.
 - all of the above.